



## Time for a new LC-MS/MS? Make a smart investment with Shimadzu.

Maximize return on investment with Shimadzu triple quad systems.

Shimadzu offers the ultimate combination of speed, sensitivity, and uptime to maximize your productivity while minimizing costs.

Consolidate your old instruments and save time and money with Shimadzu.

Learn more about Shimadzu's LC-MS/MS.  
Call (800) 477-1227 or visit us online at  
[www.ssi.shimadzu.com](http://www.ssi.shimadzu.com)

Order consumables and accessories on-line at <http://store.shimadzu.com>  
Shimadzu Scientific Instruments Inc., 7102 Riverwood Dr., Columbia, MD 21046, USA

- Ultra-fast LC-MS/MS allows comprehensive panels significantly faster than competitors
- Superior sensitivity reduces the amount of internal standards used
- Consolidating old instruments onto a faster platform reduces service contract costs

**TECHNICAL NOTE****ANTHROPOLOGY**

Sara Garcia,<sup>1</sup> B.A.; Alexander Smith,<sup>1</sup> B.A.; Christiane Baigent,<sup>1</sup> M.Sc.; and Melissa Connor,<sup>1</sup> Ph.D.

## The Scavenging Patterns of Feral Cats on Human Remains in an Outdoor Setting\*

**ABSTRACT:** Two cases of feral cat (*Felis catus*) scavenging were documented at the Forensic Investigation Research Station in Whitewater, Colorado. Human remains at the facility are placed outside, observed daily, documented with field notes, and photographed; decomposition is scored on a Likert scale. Scavenger activity is monitored with game cameras. The cases documented included: preferential scavenging of the soft tissue of the shoulder and arm, differential consumption of tissue layers, superficial defects, and no macroscopic skeletal defects. This pattern more closely parallels the documented pattern of bobcat (*Lynx rufus*) scavenging than that of domestic cats. Scavenging among felids is relatively rare, as felids typically prefer to hunt. Such cases studied in detail are relatively few, spatially relative, and lack statistical robustness. While only two examples are reported here, these cases are rare overall, and this documentation may help field investigators understand the place of feral cats within a local scavenger guild.

**KEYWORDS:** forensic science, forensic anthropology, taphonomy, feral cats, scavenging, felids

Documented cases of felid scavenging are rare (1) in part due to the fact that cats prefer to hunt rather than scavenge. Scavenging by domestic cats (*Felis catus*) is uncommon and rarely documented (2–5). Selection mechanisms rooted in the sensory characteristics of food sources may be partly responsible: (a) neophobia, the rejection of foods not previously encountered; and (b) “the novelty effect,” a preference for previously familiar foods that are spatially or temporally limited in availability (6). When felid scavenging does occur, intrafamilial variation in scavenging patterns has been documented. While domestic cats (*Felis catus*) focus on the facial region (2), larger wild felids, such as bobcats (*Lynx rufus*), focus on the postcranial tissues of the arms, hips, and thighs (1). Overall, felids tend to exploit fresh tissue across several days (1,7).

The dentition of felids is particularly well adapted for their protein dense, primarily meat-based diet. The felid dental complex (I3/3 C1/1 P3/2 M1/1) is distinct from canids (I3/I3, C1/C1, P4/P4, M2/M3), evolving together with a smaller rostrum and subsequent reduction in posterior bite force relative to canids (8,9). Compared with canids, felid incisors are smaller and specialized for grooming. Felids have long, labially oriented, cone-shaped canines designed to puncture tissue with little force (8). High shearing cusps, lack of occlusal flattening, and the scissor-like arrangement of paired carnassial teeth facilitates the efficient slicing, removal, and processing of tissue. The relatively small size, strength, and bite force of *Felis catus* may preclude their ability

to open the human thoracic cavity, resulting in the divergent patterns of inter- and intrafamilial scavenging (10). In combination, the smaller rostrum, fewer teeth, carnassial teeth, and their scissor-like arrangement results in a bite force that can shear tissue, but with less ability to break bone than canids.

Two separate incidents of feral cat scavenging of human remains occurred at Colorado Mesa University’s Forensic Investigation Research Station (FIRS), in Whitewater, Colorado. This study uses the term “feral cat” to refer to free-roaming domestic cats (*Felis catus*) that are born and live in the wild (11). Feral cats are distinct from house cats in home range size, access to preventative and reactive care, disease load, resource array, competitive behavior, and territory defense (12). House cats are defined as domestic cats that primarily derive resources from a human caregiver located at a residence that serves as the focus of the feline’s home range. The cats described in these cases are thought to be feral because: (i) the house cat maintains a home range size of 0.01–20 hectares (12), the FIRS is located approximately 310 hectares from the closest private residence; (ii) the FIRS is located 0.075 hectares from a landfill that supports a large feral cat population; and (iii) the cats present no observable indicators of ownership (e.g., tags/collars, or signs of fastidious grooming). So, while it is possible that one or both of the subjects described were house or ranch cats, the preponderance of evidence suggests these were what is commonly called feral.

Due to the prevalence of feral cats throughout the United States and the world, understanding the patterns and behaviors of these scavengers can assist in distinguishing between perimortem and postmortem tissue damage.

### Material and Methods

The FIRS is in an area that is classified as cold semiarid steppe climate in the Köppen-Geiger climate classification system, at an altitude of approximately 1457 m AMSL. This

<sup>1</sup>Forensic Investigation Research Station, Colorado Mesa University, 1100 North Ave, Grand Junction, CO, 81501, USA.

Corresponding author: Sara Garcia, B.A. E-mail: [saralouise51532@gmail.com](mailto:saralouise51532@gmail.com)

\*Presented at the 71st Annual Scientific Meeting of the American Academy of Forensic Sciences, February 18–23, 2019, in Baltimore, MD.

Received 28 June 2019; and in revised form 9 Sept. 2019, 21 Oct. 2019; accepted 22 Oct. 2019.

environment is made distinct by a paucity of moisture that affects attendant ecological relationships. Annual precipitation is less than 24 cm of rain and 19 cm of snow per year, making water a critical resource for both flora and fauna. The impact of the semiarid environment on human decomposition is also distinct; the typical trajectory of decomposition is characterized by desiccation, with full skeletonization often taking years (13).

The outdoor decomposition facility at the FIRS is fenced to preclude access by large-bodied scavengers. The fence extends below the ground and inhibits burrowing around the perimeter, but this has not deterred the extension of warren systems by expansive excavating species. The fence does not restrict the access of avian scavengers and small mammals, which can enter via burrows or through a gap between the fence and gate. The outdoor facility is home to a prairie dog (*Cynomys leucurus*) colony, the warrens of which extend to the area outside the fenced facility. Rabbits (*Sylvilagus auduboni*) also visit, but there is no evidence for long term habitation. Mice (unknown rodent species) are common and frequently nest beneath, and within, desiccated remains.

Due to the presence of small-bodied vertebrate scavengers, donors are documented in part using motion activated infrared game cameras. When tissue change consistent with scavenging is observed, game cameras are trained on the affected human remains to determine the scavenger species involved. Bodies are placed, unclothed, in a supine position on the surface. Donors are placed approximately three meters from one another. Remains are documented daily following the FIRS photography protocol (14), the region-specific Total Body Desiccation Score (TBDS) protocol devised following Connor et al. (13) and the Total Body Score (TBS) protocol (15) devised following Megysi et al. (16). As the remains become desiccated (i.e., meet or exceed a TBS score of 24), they are documented weekly. The FIRS has an on-site HOBO® weather station which records, among other data, hourly temperature. Temperature data are reported using the Celsius scale, and accumulated degree-days (ADD) are calculated by averaging the hourly temperature readings for each day, then adding that average temperature for each consecutive day from the time of donor placement.

Tissue damage consistent with scavenging is observed, photographed, and described daily. Any exposed bone is visually checked for macroscopic damage. The impacted donors remain a part of the active study cohort at the FIRS, and as such a detailed microscopic analysis of the affected bones has not been performed. Observations of tissue damage are temporally correlated with game camera images to confirm and document the presence of scavengers. These individuals are specifically monitored for scavenging until the scavenger is no longer present. While the two donors discussed below remain in the active study cohort as of this writing, active scavenging has ceased.

## Results

### Case 1

A 79-year-old woman (FIRS 17-12) was placed in the outside facility at the FIRS 13 days after death. Approximately 40 other donors were in the outdoor facility at the time of placement. Subcutaneous needles were inserted as part of an unrelated research study. Decomposition accelerated at the needle insertion sites. Scavenging began approximately 5 days after placement, near two of the needle insertion sites. Initially, circular defects on the distal upper arm, proximal to the elbow, were noted. A

game camera photographed a striped cat tearing tissue from the donor. While these images show the cat scavenging, the cat consistently scavenged in areas that were partially obstructed from view. This prevented a detailed analysis of the cat's scavenging behaviors. The damage was photographed and described the following day. The cat consumed tissue from the left arm and adjacent chest, focusing on the dermal and fat layers. In some cases, it appeared to simply peel fat from the muscle and then scavenge laterally and superficially, rather than more deeply into the muscle. To complete the unrelated research project, a cage was placed over the donor; the cage was removed after one week. Shortly thereafter, what appeared to be the same cat returned to the body. The cat continued to scavenge in the same area almost nightly for approximately 35 days. The scavenging occurred between 64 and 405 ADD and a TBS range of 8–17 (Table 1). The cat removed much of the tissue on the left breast area and along the upper left arm. No bones were exposed in the breast area, but scavenging of the arm was sufficient to expose the humerus from the proximal to the mid-shaft region. In the breast area, the fat and dermal tissue appeared to be the preferred tissue source.

Small, irregular defects were present along the margin of the scavenged area on the chest (Fig. 1). These defects impacted the outer surface of the tissue, presenting as shallow, discolored dents in the tissue. These defects were noted only on the chest and not the arm.

Along the margins of the scavenged area on the left arm, the outer layer of tissue was pulled back (reflected) rather than consumed, giving the tissue a frayed appearance (Fig. 2). In the early stages of scavenging, only the fat tissue was consumed, leaving the muscle exposed. Only after consuming most of the fat tissue on the proximal arm, did the cat begin to consume the muscle tissue, resulting in exposure of the humerus.

At no time did the cat demonstrate an interest in any of the 40-plus adjacent donors. Several new donations were placed during the scavenging period and were also monitored via game camera. The cat showed no interest in the newer donations and continued preferentially to scavenge FIRS Donor 17-12.

### Case 2

A 70-year-old autopsied man (FIRS 18-06) was placed in the outdoor facility approximately 11 days after death. Scavenging began approximately six days after placement. Unlike Case 1, FIRS staff made no attempt to prevent scavenging. The initial area impacted was the lateral left shoulder along the autopsy incision, the lower lateral abdomen, and the proximal left arm.

TABLE 1—Cat scavenging indicators observed in two cases at the FIRS.

Feature	Description
Onset of scavenging	Early decomposition (PMI 5–6 days; TBS 8–11; ADD 63–64)
Terminus of scavenging	Moist decomposition (PMI 21–40 days; TBS 16–17; ADD 214–405)
Soft tissue defects	1. Superficial circular defects peripheral to area of tissue removal 2. Linear striae peripheral to area of tissue removal
Location	Shoulder girdle and proximal arm.
Skeletal exposure	Atypical; limited to exposure of one humeral diaphysis
Skeletal defects	None observed
Skeletal disarticulation	None observed

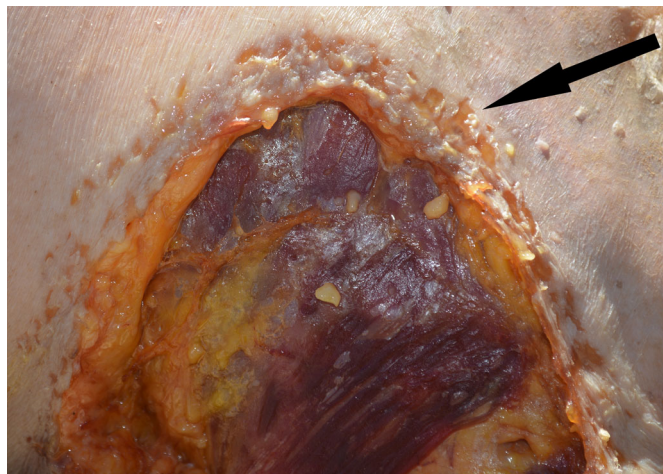


FIG. 1—Small, irregular defects peripheral to scavenging on the chest from Case 1.

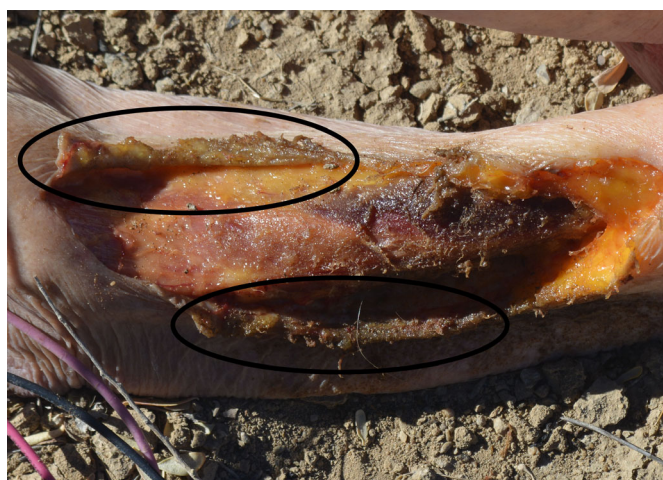

FIG. 2—Outer layers of tissue pulled back (reflected) to expose underlying tissue in Case 1.

A game camera photographed a black cat, a different animal from that which scavenged Case 1, tearing tissue from the donor. After the initial scavenging event, what appeared to be the same cat returned for 10 of the next 16 nights, then after a month-long hiatus, it returned for two nights. On each night, the cat visited the same body multiple times. The scavenging occurred between 63–339 ADD and a TBS range of 11–16 (Table 1). Scavenging stopped at the onset of moist decomposition.

Small, irregular defects were observed along the distal margin of the scavenged area on the left arm (Fig. 3). Similar defects were observed on the chest, though they were less prevalent in this region. These defects were visually consistent with the irregular defects seen on Case 1. While new defects were not observed after every scavenging event, they were present on this individual at all stages of scavenging. Unlike the cat scavenging Case 1, the cat scavenging Case 2 was not camera shy and game camera photographs show the cat's teeth superficially impacting the tissue in the area where these defects were observed.

Small, linear striae were observed on the left arm, distal to both the scavenged area and the previously described peripheral defects. These striae were accompanied by both small and large

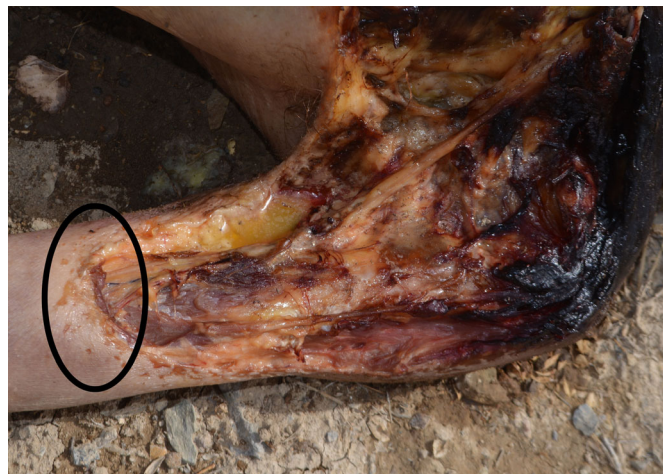

FIG. 3—Small, irregular defects peripheral to the scavenged area on the left arm in Case 2.

circular defects (Fig. 4). Game camera images from the night preceding the appearance of these defects show the cat planting its claws and standing on the affected area as it consumed tissue from the proximal arm. The cat is seen with its claws positioned and fully extended as an anchor in the area of the circular defects (Fig. 5).

What appeared to be the same cat was seen on game cameras throughout the facility but showed no interest in any of the other 40-plus adjacent donors. The cat did not scavenge new donors placed around the time of scavenging and in a similar stage of decomposition to FIRS 18-06.

## Discussion

In the few reported cases of indoor domestic *Felis catus* scavenging, the target was the face (primarily the mouth and nose), hands, and feet (2). In the documented instance of bobcat scavenging (1), the focus was on the arms, hips, and thighs. In both cases reported here, the feral cats targeted areas where the skin

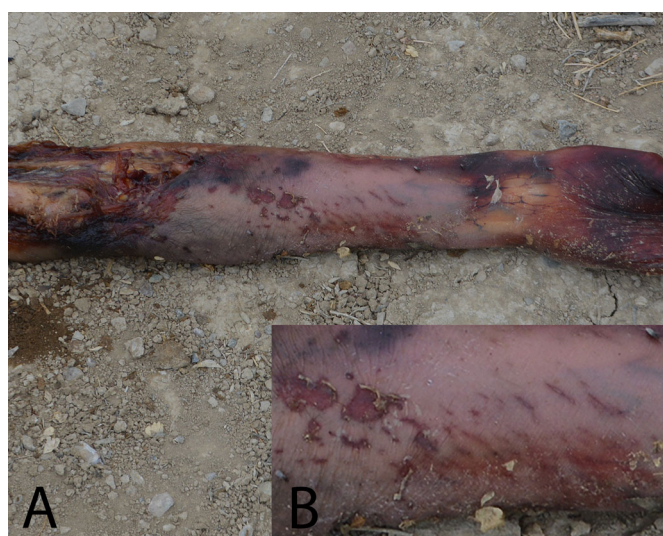


FIG. 4—(A) Small, linear striae and circular defects distal to scavenging on the left arm in Case 2. (B) Enlarged image of the same defects.



FIG. 5—Game camera image of the cat using its claws to stabilize the arm as it consumes tissue in Case 2.

had been previously penetrated. The abdomen was a secondary area of interest (Table 2). These two cases more closely parallel the reported pattern of bobcat scavenging (1) than that of the domestic *Felis catus*.

Differences in feeding behavior between domestic and feral cat groups are reported and are most often attributed to both neophobia, and the need for reflexivity in the feral cat diet as they work to meet nutritional needs (6). The novelty effect may partly explain why both cats showed a preference for a specific donor, despite the presence of adjacent donors.

Both cats showed preference for bodies in relatively early decomposition (TBS 8–16). Scavenging began when the bodies showed early signs of decomposition and ended at the onset of moist decomposition. The cessation of scavenging at the onset of moist decomposition may be explained by felids' preference for fresh tissue (1,7). In both cases, scavenging began at a similar phase of the postmortem interval (PMI) and ADD (Table 1). In case 1, the scavenging window was longer; however, the stage of decomposition at the end of scavenging was similar in both cases. This further suggests that the cats preferred tissue in earlier stages of decomposition.

In both cases, small, irregular defects were present peripheral to the scavenged area, outlining the border of the defect (Table 1). In case 1, these defects were only observed on the chest and not removed by further scavenging. In case 2, defects were present inconsistently as the cat would create the defects one night and scavenge that area the next, removing the defects. The cat did not always create these defects during scavenging, so the defects would be there one day and gone the next. Game camera images of the cat in case 2 indicate that these defects were caused by the cat's teeth as it scavenged. These defects were consistent with

those seen in case 1, though the cat in that case scavenged away from the camera and thus individual bites could not be observed. Linear striae and circular defects were also seen in case 2, present peripheral to the scavenged area. These defects correlated with game camera images of the cat using its claws to stabilize the limb as it consumed tissue elsewhere.

While there are game camera images of the cat in case 2 licking the donor, there was no clear evidence of this behavior reflected in the tissue. From game camera photographs, the marks on the tissue were created by the teeth and claws, rather than by the tongue.

The tissue removal process differed between the two cases. In case 1, the outer tissue on the left arm was pulled back (reflected) to gain access the underlying tissue. In contrast, in case 2, the different tissue layers (superficial to deep) were consumed without clear preference for tissue type.

Both the peripheral defects and the reflected tissue margins in these cases present similar to other possible postmortem changes. The small, irregular defects peripheral to the scavenged areas in both cases have some similarities to the superficial defects created by various species of ants (17–19). The defects described here were small and only observed directly peripheral to a much larger scavenged area where significant tissue removal was present. The observed pattern in ants includes only superficial defects (skin loss) that are present throughout exposed tissue and are often larger than the similar defects seen in this study (17–19). The reflected tissue in case 1 appears similar to the same feature caused by desiccation of the tissue. In this case, the edges of the tissue were fresh when the feature was initially observed and thus could not have been caused by desiccation. No macroscopic damage to the bone was observed, suggesting that the bone was not the primary target for the cats.

Both rodents and canids impact the hard tissue as well as the soft (20–24), whereas the two cases of cat scavenging described in this paper impact the soft tissue. As noted above, it is probable that the mechanics of the felid dental complex make it difficult for them to break or puncture bone as canids do, while their dramatically smaller incisors and posteriorly emphasized bite force preclude rodent-like gnawing. Rodent induced damage to soft tissue presented a layered pattern of dermal destruction. Cat induced soft tissue removal also exhibited layered destruction—characterized by removal of the fat layer before consumption of deeper muscle tissues—but did not present the differential destruction of the dermal layers, as noted by Haglund (20) for rodents. Canids showed no such delicacy, consuming all layers of tissue. Notably, the cat involved in the first case demonstrated a tendency to reflect the epidermal layers, a pattern inconsistent with canids and rodents.

Documented cases of canid scavenging included defects along the skin margin of the scavenged area such as “V” shaped puncture marks (21) and linear defects (2,24) both of which were

TABLE 2—Scavenging patterns observed in bobcats (1), domestic cats (2), and feral cats.

Characteristic	Bobcat ( <i>Lynx rufus</i> )	Feral cat ( <i>Felis catus</i> )	Domestic cat ( <i>Felis catus</i> )
Area scavenged	Arms, abdominal region, hips, and thighs	Arm, chest	Face (mouth and nose), hands, and feet
Defect Margins	Predominantly smooth	Some scalloped margins, some areas where dermal layers are reflected back to access the fat.	Unknown
Characteristics of tissue beyond margin of damage	Scratches with no patterns	Circular puncture marks, scratches	Bite marks around scavenged area
Consumption of tissue layers	Soft tissue, adipose tissue, muscle tissue	Differential consumption of fat and muscle	Unknown

attributed to canid teeth. Cat scavenging also exhibited distinct marks at the margin of the scavenged defects, but puncture marks were circular in morphology resulting from the cat's use of its claws to stabilize the body while tearing tissue with its teeth. Another characteristic of canid scavenging is disarticulation of the remains, often commencing with the upper extremities and progressing to the trunk (21). Rodents removed individual skeletal elements after the tissue was removed (20). The cats in these cases showed no proclivity for skeletal destruction or disarticulation.

In the two cases presented, scavenging of human remains by feral cats showed similar scavenging windows spanning from early decomposition to the onset of moist decomposition. Both cases showed a distinct pattern, which included: preferential scavenging of the soft tissue of the shoulder girdle and proximal arm, differential consumption of tissue layers, superficial defects peripheral to the scavenged area, and no presence of macroscopic skeletal defects.

While this study is based on two cases and thus should not be considered the pattern for all feral cats, documentation of cases such as these are necessary to begin to establish both patterns and variation in behavior. Tissue damage due to postmortem scavenging can be confused with perimortem trauma, or other forms of postmortem artifact which may analytically interfere with skeletal analysis and/or the estimation of postmortem interval. Scavenging may also conceal soft tissue trauma that has the potential to inform cause and manner of death. Documenting individually the scavengers in an overall regional scavenging guild assists investigators in discriminating between scavengers who may have targeted a decedent. Recognizing the scavenging patterns of a variety of animals is important for investigators to determine the origin of the damage and separate postmortem from perimortem damage.

#### Acknowledgments

Without the generous donations of the families and donors this research would not have been possible. Stephanie Matlock assisted in identifying various species of fauna. In addition to the authors, a number of FIRS interns collected data, photographed the remains, and assisted in putting data into a database. Without this assistance, the paper would not be possible.

#### References

- Ripley A, Larison NC, Moss KE, Kelly JD, Bytheway JA. Scavenging behavior of *Lynx rufus* on human remains during the winter months of Southeast Texas. *J Forensic Sci* 2012;57(3):699–705.
- Rossi ML, Shahrom AW, Chapman RC, Vanezis P. Postmortem injuries by indoor pets. *Am J Forensic Med Pathol* 1994;15(2):105–9.
- Sperhake JP, Tsokos M. Postmortem animal depredation by a domestic cat. *Arch Kriminol* 2001;208(3–4):114–9.
- Suntirukpong A, Mann RW, DeFreytas JR. Postmortem scavenging of human remains by domestic cats. *Siriraj Med J* 2017;69(6):384–7.
- Moran NC, O'Connor TP. Bones that cats gnawed upon: a case study in bone modification. *Circaea* 1992;9(1):27–34.
- Bradshaw JWS, Healey LM, Thorne CJ, Macdonald DW, Arden-Clark C. Differences in food preferences between individuals and populations of domestic cats *Felis silvestris catus*. *Appl Anim Behav Sci* 2000;68(3):257–68.
- Krofel M, Kos I, Jerina K. The noble cats and the big bad scavengers: effects of dominant scavengers on solitary predators. *Behav Ecol Sociobiol* 2012;66(9):1297–304.
- Parkinson JA, Plummer T, Hartstone-Rose A. Characterizing felid tooth marking and gross bone damage patterns using GIS image analysis: an experimental feeding study with large felids. *J Hum Evol* 2015;80:114–34.
- Meachen-Samuels J, Valkenburgh BV. Craniodental indicators of prey size preference in the Felidae. *Biol J Linn Soc Lond* 2009;96(4):784–99.
- Sincerbox SN, DiGangi EA. What big teeth you have: taphonomic signatures of North American scavengers. In: Sincerbox SN, DiGangi EA, editors. *Forensic taphonomy and ecology of North American scavengers*. San Diego, CA: Elsevier, 2018;64–148.
- Taetzsch SJ, Gruszynski KR, Bertke AS, Dubey JP, Monti KA, Zajac AM, et al. Prevalence of zoonotic parasites in feral cats of Central Virginia, USA. *Zoonoses Public Health* 2018;65:728–35.
- Hall CM, Bryant KA, Haskard K, Major T, Bruce S, Calver MC. Factors determining the home ranges of pet cats: a meta-analysis. *Biol Cons* 2016;203:313–320.
- Connor M, Baigent C, Hansen ES. Measuring desiccation using qualitative changes: a step toward determining regional sequences. *J Forensic Sci* 2019;64(4):1004–11.
- Baigent C. Field photography protocol. *Forensic Investigation Research Station*. In: Connor M, series editor. *FIRS Technical Manual Series #3*. Grand Junction, CO: Colorado Mesa University, 2017.
- Baigent C. Data collection: total body score. *Forensic Investigation Research Station*. In: Connor M, series editor. *FIRS Technical Manual Series #1*. Grand Junction, CO: Colorado Mesa University, 2017.
- Megyesi MS, Nawrocki SP, Haskell NH. Using accumulated degree-days to estimate the postmortem interval from decomposed human remains. *J Forensic Sci* 2005;50(3):618–26.
- Campobasso CP, Marchetti D, Introna F, Colonna MF. Postmortem artifacts made by ants and the effect of ant activity on decomposition rates. *Am J Forensic Med Pathol* 2009;30(1):84–7.
- Byard RW. Autopsy problems associated with postmortem ant activity. *Forensic Sci Med Pathol* 2005;1(1):37–40.
- Byard RW, Heath KJ. Patterned postmortem ant abrasions outlining clothing and body position after death. *J Forensic Legal Med* 2014;26:10–3.
- Haglund WD. Rodents and human remains. In: Haglund WD, Sorg MS, editors. *Forensic taphonomy: the postmortem fate of human remains*. Boca Raton, FL: CRC Press, 1997;405–14.
- Haglund WD. Dogs and coyotes: postmortem involvement with human remains. In: Haglund WD, Sorg MS, editors. *Forensic taphonomy: the postmortem fate of human remains*. Boca Raton, FL: CRC Press, 1997;367–81.
- Steadman DW, Worne H. Canine scavenging of human remains in an indoor setting. *Forensic Sci. Int* 2007;173(1):78–82.
- Synstelién JA. *Studies in taphonomy: bone and soft tissue modifications by postmortem scavengers [dissertation]*. Knoxville, TN: University of Tennessee Knoxville, 2015.
- Rothschild MA, Schneider V. On the temporal onset of postmortem scavenging “Motivation” of the animal. *Forensic Sci Int* 1997;89(1–2):57–64.